



Contents lists available at SciVerse ScienceDirect

## International Journal of Surgery

journal homepage: www.theijs.com



Original research

## Dye assisted lymphatic sparing subinguinal varicocelectomy. A prospective randomized study

Mohamed E. Abd Ellatif, Ayman El Nakeeb\*, Ashraf M. Shoma, Ashraf E. Abbas, Walleed Askar, Nashat Noman

Mansoura University Hospital, General Surgery Department, Mansoura, Egypt

## ARTICLE INFO

## Article history:

Received 27 June 2011

Accepted 15 July 2011

Available online 23 August 2011

## Keywords:

Varicocele

Methylene blue

Lymphatic vessels

Subinguinal varicocelectomy

Hydrocele

Testicular edema

## ABSTRACT

**Background:** Division of lymphatic vessels during varicocelectomy could lead to hydrocele formation and decrease in testicular function due to testicular edema. We determined if the use of methylene blue combined with optical magnification reduces the incidence of post-varicocelectomy hydrocele.

**Methods:** Consecutive patients treated for varicocele at our institution were evaluated for inclusion. Participants were randomly allocated to receive either subinguinal varicocelectomy after 2 ml intratunical space injection of methylene blue and group 2 in whom no mapping technique was adopted during subinguinal varicocelectomy. After surgery, the patients were assessed at 2 weeks, 6 and 12 months for hydrocele, testicular edema, varicocele recurrence, atrophy, pain or other complications with mean follow-up was  $15 \pm 7$  months.

**Results:** Eighty patients with varicocele were randomized and completed the study. There were no intra complications in either group. In group (1) no patient had a hydrocele after surgery. By contrast, in group (2) there were four cases of secondary hydrocele (10%;  $P = 0.041$ ); no testicular hypertrophy was observed following lymphatic sparing surgery; One patient in each group had varicocele recurrence. Pregnancy was reported in 30 patients (37.5%) during the follow-up period, 17 of them (42.5%) were group (1) difference was not significantly different among both groups.

**Conclusions:** Subinguinal varicocelectomy using combination of optical magnification and lymphatic staining (methylene blue) offers simple and quick preservation of the draining lymphatic vessels and avoids secondary hydrocele formation.

ClinicalTrials.gov ID: NCT01259258

© 2011 Surgical Associates Ltd. Published by Elsevier Ltd. All rights reserved.

## 1. Introduction

A clinical varicocele is observed in 10–20% of the general population, in 35–40% of patients with primary infertility and in up to 80% of patients with secondary infertility<sup>1</sup> Varicocelectomy is indicated in the case of infertility, when the testicular volume is decreased, such as in adolescents, and when associated with persistent pain.<sup>2</sup>

The ideal method of spermatic vein ligation for treating varicocele is still a matter of controversy. No general agreement has been reached on the technique of varicocele ligation, many surgical approaches to transect the internal spermatic veins, such as retroperitoneal approach by Palomo,<sup>3</sup> trans-inguinal ligation by

Ivanissevich,<sup>4</sup> subinguinal ligation by Marmar,<sup>5</sup> and laparoscopic supra-inguinal ligation. Each technique has its own advantages and disadvantages, and conflicting results have been obtained from different studies.<sup>6,7</sup>

Hydrocele formation is the most common complication reported after nonmicroscopic varicocelectomy. The incidence of this complication varies from 3% to 33% (average about 7%).<sup>8</sup> Lymphatic obstruction is more likely than venous obstruction to be the cause of this complication.<sup>9,10</sup> Moreover, it was reported that impaired lymphatic drainage also impairs testicular function and that postoperative catch up growth is due to interstitial edema. Even testicular histology is changed due to lymphatic stasis.<sup>11</sup>

There are different approaches to preserve lymphatic drainage; For example, microscopic varicocelectomy,<sup>12</sup> using laparoscopic varicocelectomy,<sup>13</sup> lymphatic hydrodissection,<sup>14</sup> and dye assisted technique using methylene blue<sup>15</sup> or isosulfan blue,<sup>16</sup> to help identify and preserve lymphatic vessels during varicocelectomy.

\* Corresponding author. General Surgery, Mansoura University, Mansoura University Hospital, Egypt. Tel.: +0502353430, +0502251543, +106752021 (mobile).

E-mail address: elnakeebayman@yahoo.com (A. El Nakeeb).

The purpose of this study was to evaluate the feasibility of methylene blue based lymphatic vessel preservation and its impact on the complications of subinguinal varicocelectomy in a randomized prospective trial.

## 2. Patients and method

Consecutive patients who were treated for varicocele at Mansoura University Hospital, Mansoura, Egypt, during the period from January 2008 through Feb. 2010 were eligible for the study.

Varicocele was primarily diagnosed by physical examination with the patient in an erect position. All findings were confirmed by color Doppler ultrasound. The varicocele was graded from I to III according to severity (DubineAmelar's classification).<sup>17</sup>

Testicular volume was measured ultrasonographically using the formula:  $0.71 \times \text{Length} \times \text{Width} \times \text{Height}$ . Testicular hypotrophy defined as 20% volume or greater differential between testicles.<sup>18</sup> Hypertrophy of the left testicle was defined as at least a 10% increase in size over the right testicle.<sup>11</sup>

Inclusion criteria: all left sided varicocele with impaired sperm counts, testicular pain and/or testicular atrophy. Exclusion criteria were preexisting hydrocele, previous groin surgery, concomitant hernia, allergy against methylene blue. All patients had undergone two seminal analyses at a 15-day interval before and 6 months after the operation. The mean value of these 2 tests was considered that showed at least 1 abnormal parameter (motility less than 50%, count less than 20 million and velocity abnormal forms of more than 40%, on computer-assisted semen analysis).<sup>6</sup>

Informed consent was obtained from all patients to be included in the study, after explanation of the nature of the disease and possible treatment. The study was approved by the local ethics committee.

Randomization was achieved through a computer-generated schedule, and the results were sealed into envelopes. The envelopes were drawn and opened by a nurse not otherwise engaged in the study in the operating room. The patients were then randomized into two groups: Group 1 underwent subinguinal varicocelectomy with dye assisted using methylene blue group II underwent the conventional subinguinal varicocelectomy without using dye.

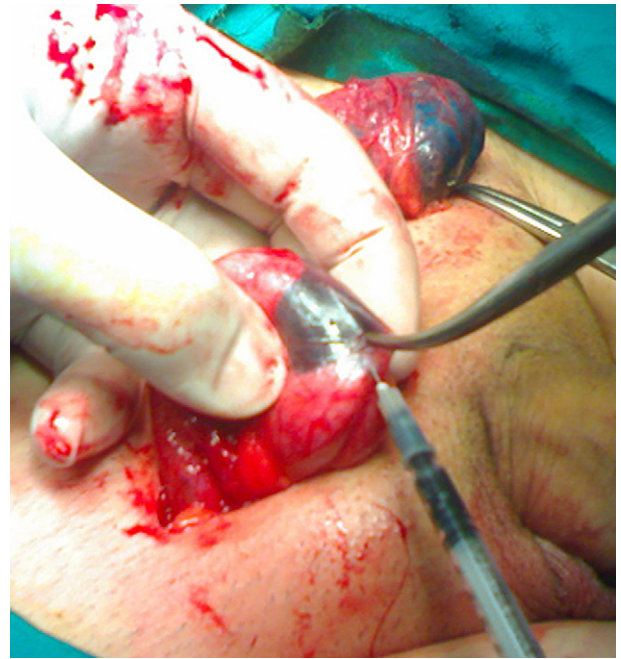### 2.1. Operative procedure

A 3-cm transverse skin incision was made directly over the external ring. The subcutaneous tissue was then dissected until the spermatic cord was identified. The spermatic cord was then elevated into the wound using gentle traction with a Babcock forceps.

Mapping of testicular lymphatics was achieved by injection of 2 ml of methylene blue with a 30-G needle into the space between the tunica vaginalis and tunica albuginea. Gentle manipulation of the testis and hemiscrotum was done after injection for a few minutes (Fig. 1).

The cremasteric veins passing on the under surface of the cord were then dissected under loupe magnification and tied with absorbable 3-0 vicryl ties. The fascial layers of the cord were then opened. The vas deferens and its vessels were identified and preserved in their posterior fascial compartment. The testicular (internal spermatic) artery was then identified and preserved with the aid of the surgical loupe (3× magnification) and irrigated with diluted warm papaverine (2 mL; 30 mg papaverine was diluted in 10 mL saline).

All internal spermatic veins were ligated using 3-0 vicryl, the internal spermatic artery and numerous blue stained lymphatic vessels only were left behind (Figs. 1–3). The subcutaneous tissue



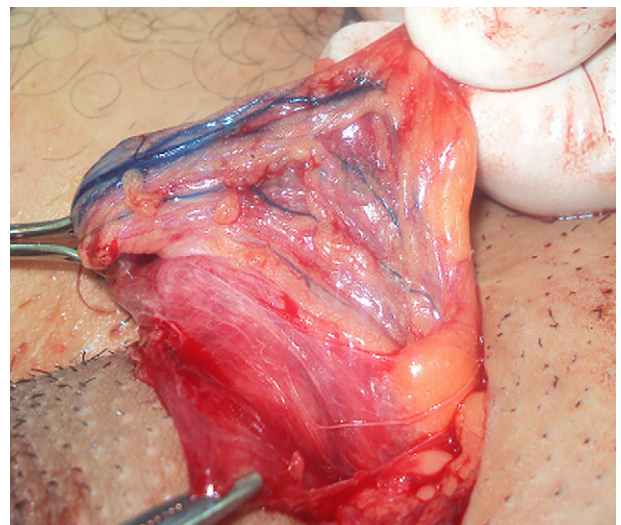
**Fig. 1.** Injection of 2 ml of methylene blue with a 30-G needle into the space between the tunica vaginalis and tunica albuginea.

was closed with 4-0 Vicryl sutures and the skin approximated using a running 4-0 white Vicryl stitch. All operations were performed by the same surgical team at the same university hospital.

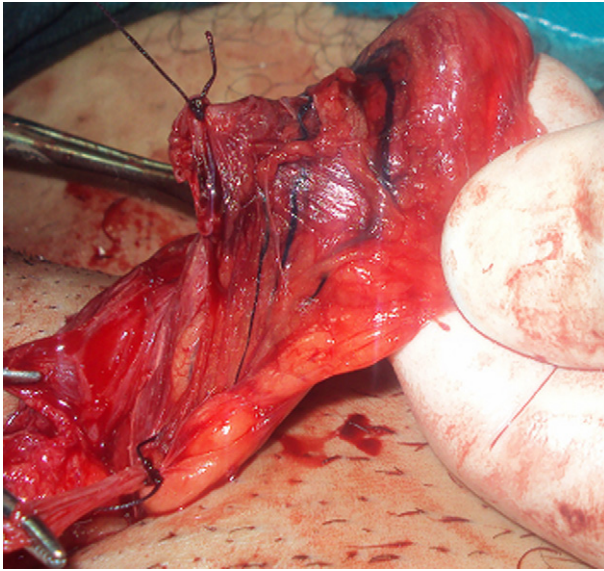
In the other group, the same technique was carried out but with one difference that no methylene blue and the lymphatics were distinguished as colorless tubular structures accompanied by a small serpentine venule using the optical magnification.

### 2.2. Postoperative care

Patients were discharged the following day to allow for assessment of any immediate postoperative complications (eg, hematoma). A prescription of a non-steroidal anti-inflammatory drug was given (diclofenac 50 mg orally, whenever needed). Patients returned 5 days postoperatively for a wound check and were asked to return after 2 weeks, 6 months for and 12 months.



**Fig. 2.** Mapping of testicular lymphatics after injection of methylene blue.



**Fig. 3.** All internal spermatic veins were ligated using 3-0 vicryl, the internal spermatic artery and numerous blue stained lymphatic vessels only were left behind.

All assessments were conducted by investigators who were blinded to the experimental condition. Primary outcome assessment was postoperative complications (hydrocele and testicular hypertrophy), and secondary outcomes assessment were analgesia, resolution of varicocele, resolution of pain, pregnancy rate, recurrence.

The evaluations included physical examination and ultrasonography of the scrotum with Doppler assistance and also, the semen analysis findings. The mean follow-up was  $15 \pm 7$  months.

### 2.2.1. Statistical analysis

The statistical analysis of the data in this study was preferred using the SPSS version 10. Analysis of data was by intention-to-treat. For continuous variables, descriptive statistics were calculated and were reported as mean  $\pm$  SD. Categorical variables were described using frequency distributions. The Student's *t*-test for paired samples was used to detect differences in the means of numerical variables, Chi-square test was used for nominal variables and Fisher's exact test was used in cases with low expected frequencies. *P* values  $<0.05$  were considered to be significant.

## 3. Results

### 3.1. Patients' characteristics

The study flow chart is shown in Fig. 4. Of 83 consecutive patients seen during the recruiting period, 80 patients were eligible and entered the study. The mean age was  $22.5 \pm 4.8$  (range, 18–33) years.

The patient characteristics are listed in Table 1, no intergroup differences were observed in terms of age, indication of varicocele, or varicocele grade.

#### 3.1.1. Surgical outcome

**3.1.1.1. Intraoperative.** Lymphatic vessel staining was successful in all patients group 1; after staining the draining lymphatics were clearly identified by their bluish appearance and could be easily preserved. No intraoperative complications occurred. There was no hypersensitivity or allergy to methylene blue.

Mean operative time using the methylene blue was longer than with conventional technique but the difference was not statistically

significant (Table 2). The vas deferens and its vessels were successfully identified and preserved in all cases. An average of two external spermatic veins and average six internal spermatic veins were identified and ligated, the internal spermatic artery was identified and spared in all patients. Blood loss was minimal in all cases.

#### 3.1.2. Postoperative

Almost all patients didn't need postoperative analgesia, only 7 patients (3 from the 1st group and 4 from the 2nd one) who ask for a single NSAID dose. Mean length of hospitalization was  $1.35 \pm 0.53$  days in group 1 Vs  $1.47 \pm 0.54$  days (Table 2). No wound or genital infections occurred during the early postoperative period, and no hematoma or bleeding occurred. All patients came for their scheduled follow-up visits.

Three parameters were used to assess patient fertility (Table 3): sperm count per ml, percent normal morphology and percent fast linear motility 60 min after ejaculation. Pretreatment values showed no statistical differences between the two groups.

A comparison among the two study groups between the mean preoperative and postoperative semen parameters showed significant improvement in all parameters, indicating a positive increase after treatment, the increase was more evident in group 1 than group 2 but the difference was not statistically significant. Pregnancy was reported in 30 patients (37.5%) during the follow-up period, 17 of them (42.5%) were group 1 ( $P = 0.359$ ). difference was not significantly different among the two groups (Table 2).

In group 1, no patient had a hydrocele after surgery. By contrast, in group 2 (surgery alone) there were four cases of secondary hydrocele (10%;  $P = 0.041$ ) (Table 2). Three cases of them resolved by 3 months without any intervention and one patient didn't show improvement with follow-up. He subsequently underwent hydrocelectomy at 13 months after the primary surgery.

Of the 2 patients with recurrence among the 80 patients (2.5%) (One case in each group), Color Doppler ultrasonography, showing the presence of reflux in the involved veins, confirmed the diagnosis of varicocele recurrence. Both of them were followed up and no one needed repeat intervention. Of the 21 patients who presented with scrotal discomfort or pain, 18 (85.7%) (11 cases belonged to group 1 and the remaining 9 cases in group 2) achieved complete resolution of their symptoms, and the other 4 had partial resolution of pain.

Left testicular size before and following treatment is summarized in Table 4 for groups, two weeks and 6 months after surgical treatment. Volume enlargement of the left testicle was significantly higher ( $p = 0.04$ ) in group 2 than in group 1 at 2 weeks and 6 months follow-up, indicating development of left testicular hypertrophy (Table 4).

## 4. Discussion

Varicocele is still without a 'gold standard' treatment. This is confirmed by the high rate of recurrence or complications that afflicts the different therapeutic choices.<sup>15</sup>

Mean operative time in group 1 was longer than group 2 ( $42.1 \pm 9.87$ ) and ( $37.5 \pm 6.4$  min) respectively but the difference was not statistically significant ( $p = 0.23$ ), this insignificant difference may be attributed to the little time consumed by dye injection and time passed waiting for staining of the lymphatics which ranged from 2 to 7 min. after injection. Schwentner et al. noticed dye assisted is significantly shorter ( $p \geq 0.001$ ).<sup>19</sup>

In our series, most of our patients were sent home 1 day after the procedure, no allergy to methylene blue and no case of genital or inguinal wound infection, these results were similar to others in the literature.<sup>6,12</sup> Almost all patients didn't need postoperative

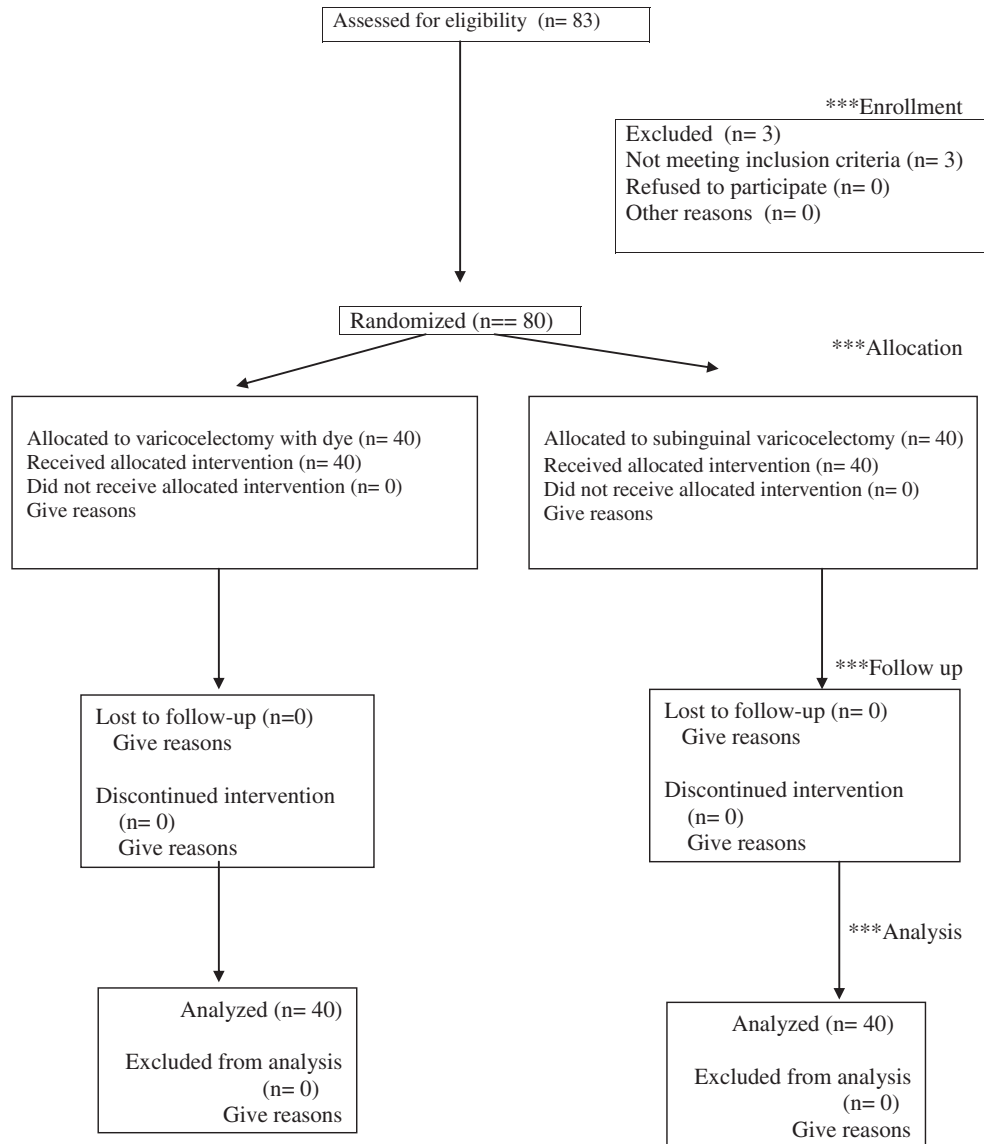


Fig. 4. Flow Diagram of the progress through the phases of a randomized trial (i.e., enrollment, intervention allocation, follow-up, and data analysis).

analgesia; this is because in the subinguinal approach there is no need to open the muscle or aponeurosis, similar to others,<sup>20</sup> while others show different results.<sup>6</sup>

The aim of the present study was to eliminate postoperative hydrocele by optimizing the identification of the lymphatics using

methylene blue, no case developed hydrocele in the methylene group, by contrast, in group 2 there were four patients of secondary hydrocele (10%);  $p = 0.41$ ) because it is not proven to discriminate microscopically between isolated lymphatic vessels and very small veins, in spite of the use of optical magnification.<sup>18</sup> Oswald et al.<sup>16</sup> first described the use of isosulphan blue in varicocele surgery, there was no postoperative hydrocele formation. Riccabona et al.<sup>21</sup> sequentially investigated four surgical techniques for treating varicocele in adolescents including vital-dye application. Schwentner

Table 1 Patients characteristics.

Variable	Group 1 (40)	Group 2 (40)	P value
Age (years)	23.5 ± 4.8 <sup>18–32</sup>	21.5 ± 4.8 <sup>17–33</sup>	0.234
symptoms			
Infertility	24 (60%)	27 (67.5%)	0.488
Pain	12 (30%)	9 (22.5%)	0.449
Atrophy	4 (10%)	4 (10%)	1.00
Grade of varicocele			
Grade I	4 (10%)	4 (10%)	1.00
Grade II	22 (35%)	20 (50%)	0.699
Grade III	14 (35%)	16 (40%)	0.654

Table 2 Operative time, hospital stay and outcome among both groups.

Variable	Group 1 (40)	Group 2 (40)	P value
Operative time (min)	42.1 ± 9.87	37.5 ± 6.4	0.23
Hospital stay (days)	1.35 ± 0.53	1.47 ± 0.54	0.275
Pregnancy	17 (42.5%)	13 (32.5%)	0.359
Hydrocele	0 (0%)	4 (10%)	0.041
Recurrence	1 (2.5%)	1 (2.5%)	1.00

**Table 3**  
Pre and postoperative semen parameters.

Variable	Group 1 (40)	Group 2 (40)	P value
Semen count/ml			
Preop	27 ± 19.6	25 ± 18	0.541
Postop	40.6 ± 9	37 ± 12.4	0.342
P value	0.001	0.001	
Motility			
Preop	27 ± 6.6	28.7 ± 6.3	0.731
Postop	39.6 ± 6.2	37.1 ± 6.1	0.153
P value	0.001	0.001	
Morphology (%)			
Preop	19.7 ± 3.3	21.5 ± 4.6	0.127
Postop	35.1 ± 4.4	33 ± 3.2	0.152
P value	0.001	0.001	

et al.<sup>19</sup> compared the occurrence of postoperative hydrocele in 50 adolescents randomly assigned to undergo laparoscopic varicocelectomy with or without isosulfan blue. at 3 months after surgery, the incidence of hydrocele was 0% and 20%, respectively ( $P = 0.025$ ).

Kocvara et al. demonstrate a decrease in testicular function in those patients with post-varicocelectomy testicular edema, and they stress the importance of lymphatic drainage preservation to ensure a better andrological outcome.<sup>11</sup> They concluded that lymphatic sparing is not only important to prevent hydrocele but also to optimize the andrological outcome. Given these data, some controversies on the relevance and outcome of varicocelectomy might be explained by relative lymphatic stasis being detrimental for proper spermatogenesis the same result was supported experimentally by Perez-Clavier and Harrison<sup>22</sup> and Wenzel,<sup>23</sup> they detected radially fragmented tubules and disorganized late stages of spermatogenesis after lymphatic ligation close to the testis or ligation of the main lymphatic trunk in its abdominal course respectively.

In our patients, no testicular hypertrophy was observed following lymphatic sparing surgery. At 6 months follow-up, no difference in left testicular size was observed in group 1 as compared to group 2. Similarly, Laven et al. found minimal change in testicular size (from 9.2% to 4.7%) following lymphatic sparing embolization.<sup>24</sup> Thus, part of the so-called reversal of testicular growth following varicocelectomy<sup>25</sup> may be attributed to testicular edema associated with the division of lymphatic vessels and may only in part be related to any real testicular growth.

In the present study, we reported an overall improvement of semen quality in 69% of our 80 patients who underwent varicocelectomy. This rate of improvement matches those of previous studies with rates of 51–79% (26, 27). Furthermore, we reported an overall pregnancy rate of 37.5% at 1 year, in agreement with various previous studies reporting a pregnancy rate of 24–71%.<sup>28,29</sup> However, several published studies have failed to demonstrate significant improvement after varicocelectomy.<sup>30,31</sup> No case of testicular atrophy became apparent in either group due preservation of internal spermatic artery and this result is similar to others.<sup>2</sup>

We observed a single varicocele recurrence in each group, this low rate of recurrence is attributed to using of optical magnification during the spermatic vein ligation which helps to deal with even very small veins, our data is consistent with other reported series.<sup>32,33</sup>

Postoperative lymphatic stasis following varicocelectomy appears to be of critical relevance for the final outcome.<sup>11</sup>

**Table 4**  
Pre and postoperative left testicular volume.

Variable	Group 1 (40)	Group 2 (40)	P value
Preop test. volume	16 ± 3.7	17.3 ± 4.7	0.380
2 weeks test. vol	18.4 ± 3.5	23.6 ± 4.2	0.001
6 months test. vol	17.9 ± 3.5	21.6 ± 3.9	0.001

Preservation of lymphatics during surgery avoids postoperative hydrocele formation. Still all available techniques for varicocelectomy leave a certain rate of lymphatic disruption and hydrocele.<sup>32</sup> As shown in this study the combination of optical magnification varicocelectomy and lymphatic staining guarantees simple and quick preservation of the draining lymphatic vessels. Hydrocele, the most common postoperative complication, was completely avoided without any additional risk to the patient. Moreover, methylene blue is inexpensive and already established in the clinical routine providing lymphatic staining.<sup>6,12</sup> Based on other studies, lymphatic tracing can further optimize lymphatic sparing and will therefore substantially influence the outcome of subinguinal varicocelectomy by reducing its main operative comorbidity.<sup>15,21</sup> We therefore advocate using the subinguinal varicocelectomy with lymphatic preservation.

## 5. Conclusions

Subinguinal varicocelectomy using combination of optical magnification and lymphatic staining (methylene blue) offers simple and quick preservation of the draining lymphatic vessels and avoids secondary hydrocele formation. Also, testicular edema can be avoided.

### Conflict of interest

None declared.

### Funding

No financial support.

### Ethical approval

This paper was approved by local ethical committee.

## References

- Schlesinger MH, Wilets IF, Nagler HM. Treatment outcome after varicocelectomy. *Urol Clin North Am* 1994;**21**:517–29.
- Schwentner C, Oswald J, Lunacek A, Deibl M, Bartsch G, Radmayr C. Optimizing the outcome of microsurgical subinguinal varicocelectomy using isosulfan blue: a prospective randomized trial. *J Urol* 2006;**75**:818–9.
- Palomo A. Radical cure of varicocele by a new technique: preliminary report. *J Urol* 1949;**61**:604–7.
- Ivanisovich O. Left varicocele due to reflux: experience with 4470 operative cases in 42 years. *J Int Coll Surg* 1960;**34**:742–55.
- Marmar JL, Debenedictis TJ, Prasis D. The management of varicoceles by microdissection of the spermatic cord at the external ring. *Fertil Steril* 1985;**43**:583–5.
- Ghanem H, Anis T, El-Nashar A, Shamloul R. Subinguinal microvaricocelectomy versus retroperitoneal varicocelectomy: comparative study of complications and surgical outcome. *Urology* 2004;**64**:1005–9.
- Zini A, Fischer A, Bellack D, Noss M, Kamal K, Chow V, et al. Technical modifications of microsurgical varicocelectomy can reduce operating time. *Urology* 2006;**67**:803–6.
- Gorber ED, Chan PT, Zini A, et al. Microsurgical treatment of persistent or recurrent varicocele. *Fertil Steril* 2004;**82**:718–22.
- Szabo R, Kessler R. Hydrocele following internal spermatic vein ligation: a retrospective study and review of the literature. *J Urol* 1984;**132**:924.
- Walsh PC, White Jr RL. Balloon occlusion of the internal spermatic vein for the treatment of varicoceles. *JAMA* 1981;**246**:1701.
- Kocvara R, Dolezal J, Hampel R, Povysil G, Dvoracek KJ, Hill M, et al. Division of lymphatic vessels at varicocelectomy leads to testicular oedema and decline in testicular function according to the LH-RH analogue stimulation test. *Eur Urol* 2003;**43**:430–5.
- Lemack GE, Uzzo RG, Schlegel PN, Goldstein M. Microsurgical repair of the adolescent varicocele. *J Urol* 1998;**160**:179–81.
- Kattan S. The impact of internal spermatic artery ligation during laparoscopic varicocelectomy on recurrence rate and short post operative outcome. *Scand J Urol Nephrol* 2001;**35**:218–21.
- Atteya A, Amer M, AbdelHady A, Al-Azzizi H, Ismael E, Abdel-Gabbar M, et al. Lymphatic vessel hydrodissection during varicocelectomy. *Urology* 2007;**70**:165–7.
- Alessio AD, Piro E, Beretta F, Brugnani M, Marinoni F, Abati L. Lymphatic preservation using methylene blue dye during varicocele surgery: a single-center retrospective study. *J Pediatr Urol* 2008;**4**:138–40.

16. Oswald J, Korner I, Riccabona M. The use of isosulphan-blue to identify lymphatic vessels in high retroperitoneal ligation of adolescent varicocele – avoiding postoperative hydrocele. *BJU Int* 2001;**87**:502–4.
17. Dubin L, Amelar RD. Varicocelectomy as therapy in male infertility. A study of 504 cases. *J Urol* 1975;**113**:640.
18. VanderBrink BA, Palmer LS, Gitlin J, Franco I, Levitt SB, Franco I. Lymphatic-sparing laparoscopic varicocelectomy versus microscopic varicocelectomy: is there a difference? *Urology* 2007;**09**:036.
19. Schwentner C, Radmayr C, Lunacek A, Gozzi C, Pinggera GM, Neururer R, et al. Laparoscopic varicocele ligation in children and adolescents using isosulphan blue: a prospective randomized trial. *BJU Int* 2006;**98**:861–5.
20. Min-Che T, William JH, Kuang-Kuo C. Modified subinguinal varicocelectomy for painful varicocele and varicocele associated infertility. *J Chin Med Assoc* 2004;**67**:296–300.
21. Riccabona M, Oswald J, Koen M, Lusuuardi L, Radmayr C, Bartsch G. Optimizing the treatment of boys with varicocele: sequential comparison of 4 techniques. *J Urol* 2003;**169**:666–8.
22. Pérez-Clavier P, Harrison RG. The effect of interruption of lymphatic drainage from the rat testis. *J Pathol* 1978;**124**:219–25.
23. Wenzel J. U<sup>ber</sup> die Reageration der Lymphgefä<sup>ss</sup>e bei Fibrosis testis nach Insuffizienz der Lymphstro<sup>m</sup>ung. *Z Mikr-Anat Forsch* 1967;**7**:90–107.
24. Laven JSE, Haans LCF, WPTThM Mali, Velde ER, Wensing CJG, Eimers JM. Effect of varicocele treatment in adolescents: a randomized study. *Fertil Steril* 1992;**58**:756–62.
25. Kass EJ, Belman AB. Reversal of testicular growth failure by varicocele ligation. *J Urol* 1987;**137**:475–6.
26. Madgar I, Weissenberg R, Lunenfeld B, Karasik A, Goldwasser B. Controlled trial of high spermatic vein ligation for varicocele in infertile men. *Fertil Steril* 1995;**63**:120–4.
27. Kim ED, Leibman BB, Grinblat DM, Lipshultz LI. Varicocele repair improves semen parameters in azoospermic men with spermatogenic failure. *J Urol* 1999;**162**:737–40.
28. Vermeulen A, Vanderweghe MN, Deslypere JP. Prognosis of subfertility in men with corrected or uncorrected varicocele. *J Androl* 1986;**7**:147–55.
29. Lund L, Larsen SB. A follow-up study of semen quality and fertility in men with varicocele testis and in control subjects. *Br J Urol* 1998;**82**:682–6.
30. Minevich E, Wacksman J, Lewis AG, Sheldon CA. Inguinal microsurgical varicocelectomy in the adolescent: technique and preliminary results. *J Urol* 1998;**158**:1022–4.
31. Silveri M, Adorisio O, Pane A, Colajacomo M, De Gennaro M. Subinguinal microsurgical ligation: its effectiveness in pediatric and adolescent varicocele. *Scand J Urol Nephrol* 2003;**37**:53–4.
32. Richter F, Stock JA, LaSalle M, Sadeghi-Nejad H, Hanna MK. Management of prepubertal varicoceles—results of a questionnaire study among pediatric urologists and urologists with infertility training. *Urology* 2001;**58**:98–102.
33. Amelar RD. Early and late complications of inguinal varicocelectomy. *J Urol* 2003;**170**:366.